

This is an open-access article distributed under the terms of the Creative Commons Attribution License, which permits unrestricted use, distribution, and reproduction in any medium, provided the original author(s) and source are credited.



ISSN: 2329-6895

Journal of Neurological Disorders

**The International Open Access
Journal of Neurological Disorders**

**Special Issue Title: Frontiers in Stem cells
for Neurological Disorders**

Handling Editor

Dr. Kuldip Sidhu
University of New South Wales, Australia

Available online at: OMICS Publishing Group (www.omicsonline.org)

This article was originally published in a journal by OMICS Publishing Group, and the attached copy is provided by OMICS Publishing Group for the author's benefit and for the benefit of the author's institution, for commercial/research/educational use including without limitation use in instruction at your institution, sending it to specific colleagues that you know, and providing a copy to your institution's administrator.

All other uses, reproduction and distribution, including without limitation commercial reprints, selling or licensing copies or access, or posting on open internet sites, your personal or institution's website or repository, are requested to cite properly.

Digital Object Identifier: <http://dx.doi.org/10.4172/2329-6895.1000138>

Role of Autologous Bone Marrow Mononuclear Cells in Chronic Cervical Spinal Cord Injury-A Longterm Follow Up Study

Alok Sharma¹, Hemangi Sane², Nandini Gokulchandran¹, Pooja Kulkarni^{2*}, Nancy Thomas³, Pradnya Bhovad³, Hema Biju³, Joji Joseph³ and Prerna Badhe¹

¹Department of Medical Services and Clinical research, NeuroGen Brain and Spine Institute, Surana Sethia Hospital and Research Centre, India

²Department of Research & Development, NeuroGen Brain and Spine Institute, Surana Sethia Hospital and Research Centre, India

³Department of Neuro Rehabilitation, NeuroGen Brain and Spine Institute, Surana Sethia Hospital and Research centre, India

Abstract

Spinal cord injury often results into severe neurological deficits. Currently, there is no treatment available which can reverse the damage. Cell transplantation is a novel treatment strategy which has shown promising results in animal models of spinal cord injury. We administered fifty six chronic cervical spinal cord injury patients with autologous bone marrow mononuclear cells, intrathecally. As a part of the protocol, all the patients also underwent rehabilitation along with cell transplantation. On a mean follow up of 2 years \pm 1 month, symptoms such as trunk stability, sitting balance, trunk muscle strength, upper limb strength, standing balance, deep touch sensation, bladder sensation, spasticity and walking balance demonstrated improvements. On performing McNemars test, a significant association was found between the improvements in these symptoms and the intervention. The improvement in Functional Independence Measure (FIM) scores was statistically significant using Wilcoxon Signed Rank test. A detailed analysis of factors such as age, cause of injury, chronicity of injury and rehabilitation before the intervention was performed. Here, we also compare this chronic cervical SCI group with chronic thoracolumbar SCI patients of our previous study. Though functional improvements were observed at greater extent in chronic thoracolumbar SCI group, the results in chronic cervical SCI group were also significant. Cell transplantation may promote neurofunctional recovery and improve the quality of life of the patients with chronic cervical spinal cord injury.

Keywords: Spinal cord injury; Cervical; Chronic; Autologous; Bone marrow mononuclear cells; Intrathecal; Quality of life

Introduction

An injury to spinal cord often results into a severe neurological deficit. The spinal cord is either completely disrupted or at times there is contusion, compression or penetration of the spinal cord which can lead into necrosis, axonal loss, glial scarring, etc [1]. The demyelination of axons may lead to a permanent loss of sensorimotor functions [2]. The recovery after spinal cord injury (SCI) is restricted as intrinsic neurogenesis and replacement of disrupted myelin rarely occurs in the CNS. Hence, the spontaneous reestablishment of neural connectivity is difficult [3]. The scar also consists of axonal growth inhibitors which further limits the repair process [4].

There is no treatment strategy available which can restore the injured spinal cord. Cellular transplantation is one of the promising options currently being explored to reverse the damage. Preclinical studies have suggested that a variety of cells such as bone marrow cells, [5] olfactory ensheathing cells, [6] Schwann cells, [7] macrophages, [8] and neural progenitor cells [9] encourage functional recovery in SCI patients.

To study the benefits of cell transplantation, fifty six patients of chronic cervical SCI were administered autologous bone marrow mononuclear cells (BMMNCs), intrathecally. MNCs from the bone marrow cells are easily obtainable and have no ethical issues unlike other cells. Invitro studies have shown that these cells have an ability to differentiate into neurons, microglial cells, astrocytes, oligodendrocytes, etc [10]. They can also carry out the repair process via various paracrine activities. They promote functional recovery by inhibiting neuronal apoptosis, suppressing the inflammatory responses, enhancing neuronal and axonal regeneration and remyelination [11]. A comparison between the outcome of the intervention in the chronic cervical SCI and previously published data of chronic thoracolumbar SCI was also performed.

Material and Method

Study design

A retrospective analysis was carried out on a non-randomized sample of cervical spinal cord injury patients who underwent intrathecal transplantation of autologous bone marrow mononuclear cells. The protocol of the study was approved by The Institutional Committee for Stem Cell Research and Therapy (IC-SCRT) in accordance to the Indian Council of Medical Research (ICMR) guidelines. 56 cases of cervical SCI were included in the study.

Patient selection

Patients were selected based on the World Medical Association Declaration of Helsinki- Ethical Principles for Medical Research Involving Human Subjects [12]. The inclusion criteria were diagnosed cases of chronic cervical SCI on MRI or CT scan. The exclusion criteria were presence of respiratory distress, presence of acute infections such as HIV/HBV/HCV, malignancies and other acute medical conditions such as respiratory infection, fever, serum creatinine more than 2, hemoglobin less than 8 and pregnancy or breastfeeding. The

***Corresponding author:** Pooja Kulkarni, NeuroGen Brain and Spine Institute, Surana Sethia Hospital and Research Centre, Suman Nagar, Sion- Trombay Road, Chembur, Mumbai-400071, India, Tel: +9122-25281610/ +9122-25283706; E-mail: publications@neurogen.in

Received September 22, 2013; Accepted October 28, 2013; Published November 04, 2013

Citation: Sharma A, Sane H, Gokulchandran N, Kulkarni P, Thomas N, et al. (2013) Role of Autologous Bone Marrow Mononuclear Cells in Chronic Cervical Spinal Cord Injury-A Longterm Follow Up Study. J Neurol Disord 1: 138. doi:10.4172/2329-6895.1000138

Copyright: © 2013 Sharma A, et al. This is an open-access article distributed under the terms of the Creative Commons Attribution License, which permits unrestricted use, distribution, and reproduction in any medium, provided the original author and source are credited.

intervention was performed only after receiving an informed consent from all the patients.

Pre-intervention assessment

Before the intervention, every patient underwent a complete evaluation consisting of neurological examination, psychological examination, Manual Muscle Testing (MMT), evaluation on scales such as Functional Independence Measure (FIM) and American Spinal Injury Association scale (ASIA). They underwent routine serological, biochemical and hematological tests for medical fitness. MRI cervical spine with diffusion tensor imaging, EMG/NCV and SSEP were also performed. Mean follow up period was 2 years ± 1 month (3 months to 4 years).

Isolation of BMMNCs

48 hours and 24 hours prior to the intervention, all the patients were administered with Granulocyte-colony stimulating factor (G-CSF) injections to mobilize the cells and enhance their numbers [13]. Bone marrow aspiration procedure was carried out under local anesthesia with or without sedation depending on the individual case. Approximately 100 ml bone marrow was aspirated from the anterior superior iliac crest bone using a bone marrow aspiration needle and was collected in heparinized tubes. Mononuclear cells (MNCs) were obtained by density gradient separation. The isolated MNCs were checked for viability manually as well as confirmed on TALI machine using propidium iodide. The MNCs were checked for CD34⁺ by Fluorescence Activated Cell Sorting (FACS) using CD34 PE antibody.

Administration of BMMNCs

The separated MNCs (body weight×10⁶) were injected immediately after separation. These cells were administered intrathecally in L4-L5 using an 18G Touhy needle and catheter. The patient was administered intravenous methylprednisolone (200 mg/kg body weight) in 500 ml Ringer Lactate over one hour during the administration of the cells, to avoid immediate local reaction to the administered cells.

Neurorehabilitation

After the cell transplantation, every patient underwent a neurorehabilitation program. A personalized exercise protocol consisting of physiotherapy, occupational therapy and psychological therapy was planned. Urorehabilitation, sexual rehabilitation and bedsores management was also included.

Outcome measures

All patients included were followed-up at three months and six months post intervention and once yearly thereafter. A comprehensive neurological evaluation was carried out for every patient to note any symptomatic changes. They were reevaluated on FIM and ASIA scale to assess improvement in Quality of Life and motor and sensory recovery respectively.

Statistical Analysis

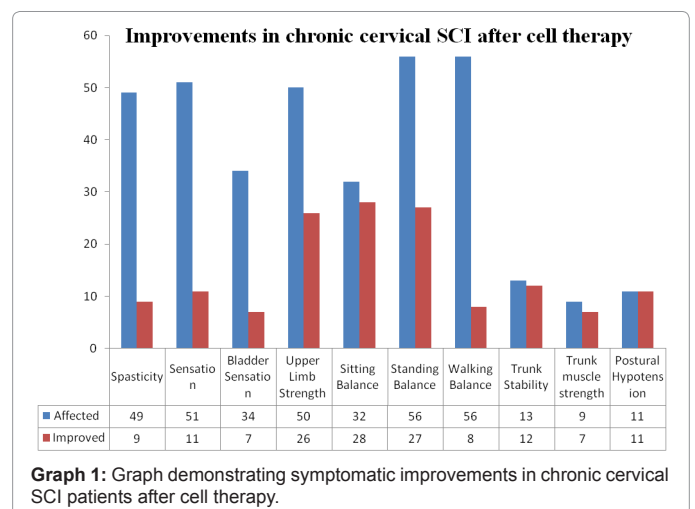
A percentage analysis was carried out for every symptom. McNemar's test was used to establish significance of the association between symptomatic changes and the intervention. FIM was analysed statistically using the Wilcoxon Signed Rank test.

Results

56 patients of cervical spinal cord injury were included in this study (Table 1). On a mean follow up of 2 years ± 1 month, out of the affected

Demographic factors		No. of Patients
Sex	Male	50
	Female	6
Age	<18 years	3
	18-35 years	34
	>35 years	19
Type of injury	Traumatic	53
	Non-traumatic	3
Cause of trauma	RTA	43
	Non-RTA	10
Duration of Injury	1-3 yrs	23
	3-5 yrs	15
	>5 yrs	18

Table 1: Demographical Data: Table demonstrating the demographical data of the patients included in the study. Total Sample Size (N=56).



Symptom	No. of patients affected	No. of patients improved	McNemars test value	P value
Spasticity	49	9	7.11111	*0.00766
Sensation	51	11	9.09091	*0.00257
Bladder Sensation	34	7	5.14286	*0.02334
Upper Limb Strength	50	26	24.03846	*<0.000001
Sitting Balance	32	28	26.03571	*<0.000001
Standing Balance	56	27	25.03704	*<0.000001
Walking Balance	56	8	6.125	*0.01333
Trunk Stability	13	12	10.08333	*0.0015
Trunk muscle strength	9	7	5.14286	*0.02334
Postural Hypotension	11	11	9.09091	*0.00257

*significant at p value ≤ 0.05

Table 2: McNemar's test: Table demonstrating the statistical analysis for each symptomatic improvement in cervical SCI using McNemar's test.

patients improvement was seen in 92.31% in trunk stability, 87.5% in sitting balance, 77.78% in trunk muscle strength, 52% in upper limb strength, 48.21% in standing balance, 21.57% in sensation, 20.59% in bladder sensation, 18.37% in spasticity and 14.29% in walking balance. All the patients who suffered from postural hypotension showed an improvement (Graph 1). On statistically analyzing this data using McNemars test, a significant association was established between the improvement in the symptom and the intervention (Table 2).

On ASIA scale, two patients showed a change from level B to C and one from level A to B and one from C to D. On FIM scale, 24 out of

Factors		Percentage improvements
Age	<18 yrs	100%
	18-35 yrs	41%
	>35 yrs	42%
Cause of Trauma	RTA	37.20%
	Non-RTA	30%
Chronicity	1-3 yrs	47.82%
	3-5 yrs	33.33%
	>5 yrs	44.44%
Rehabilitation	Done	36.84%
	Not Done	55.55%

Table 3: Percentage analysis of improvements: Table demonstrating a detailed analysis of various factors and the improvements.

Symptoms improved	Cervical SCI	Thoracolumbar SCI
Spasticity	18.37%	26%
Sensation	21.57%	28%
Bladder Sensation	20.59%	33%
Bowel Sensation	5.66%	0.9%
Sitting Balance	87.50%	81.81%
Standing Balance	48.21%	66.36
Trunk Stability	92.31%	95.65%
Postural Hypotension	100.00%	100%

Table 4: Comparison between Cervical SCI and Thoracolumbar SCI: Table comparing the outcome of cell transplantation in cervical SCI and Thoracolumbar SCI.

56 patients showed an increase in the score. On performing Wilcoxon Signed Ranks Test, Z value was -4.308 and the two-tailed p value was ≤ 0.0001 indicating significant functional improvement after the intervention. A detailed analysis of the functional improvement based on various factors such as gender, age, type of injury, cause of trauma, chronicity and rehabilitation taken prior to the intervention was also performed (Table 3).

Adverse events

No major side effects were recorded in the duration of follow up. Minor procedure related side effects such as headache, nausea, vomiting, and backache were observed in a few cases which were controlled with medications (Table 4).

Discussion

The underlying pathophysiology of spinal cord injury majorly includes a primary mechanical insult followed by a secondary cascade which includes ischemia, free radical formation, death of oligodendrocytes, release of myelin associated inhibitory molecules, glial scar formation, etc which may inhibit the regeneration of axons [14]. Further, leading to a deficit in neural conduction [15]. The management for SCI should not only aim at cell proliferation and its survival but should also encourage axonal growth, remyelination and synaptogenesis and angiogenesis [16].

Cell transplantation has gained a remarkable focus as a treatment strategy for spinal cord injury. To study its effect on chronic cervical spinal cord injury, we administered 56 patients with autologous bone marrow mononuclear cells (BMMNCs), intrathecally. Bone marrow cells can differentiate into neuronal and myelin producing cells. They guide axonal regeneration by producing extracellular matrix and also promote activation of endogenous stem cells which restructures the neural network [17,18]. For this study we chose BMMNCs, as the isolation of these cells is relatively easy and avoids any immunological rejection or ethical issues. BMMNC is a mixture of mesenchymal

stem cells, hematopoietic stem cells, macrophages, lymphocytes, endothelial progenitor cells, etc. [19]. Mesenchymal stem cells and hematopoietic cells induce a neuroprotective effect. They excrete cytokines such as thrombopoietin and interleukin 11 which help the survival and differentiation of neuronal progenitor cells [20]. Activated macrophages improve the axonal regeneration by removing the myelin debris from the site of injury [21]. Few studies have also confirmed that use of whole BMMNCs is more successful than sub fractionated cell preparations [22].

As an alternative to the direct injection into the parenchyma of the injured spinal cord, we delivered the cells intrathecally. Although, direct injection guarantees the delivery of cells to the site of injury, it involves a major surgical procedure with risk of secondary neurological damage along with other complications [23]. Intravenous (IV) delivery of cells may be safe but studies have shown that majority of cells get trapped in organs other than the target organ. They are also more susceptible to the host immune system [24]. Intrathecal mode of injection eliminates the risk of direct injection and decreased engraftment efficiency of IV injection. When magnetically labelled CD34⁺ cells were injected intrathecally in SCI patients, it was found that these cells were well tolerated and migrate efficiently to the site of injury [25].

All the patients included in the study underwent rehabilitation after cell transplantation as a part of the protocol. In animal studies, combining rehabilitation with cell transplantation has resulted in positive functional outcome [26].

On a mean follow up of 2 years \pm 1 month, no adverse events related to the intervention were recorded. On statistically analyzing the data, it was evident that cell therapy promotes functional recovery in cervical SCI. A significant change was also recorded in the FIM score after the intervention. We observed a significant improvement in the upper limb functions which might have enhanced the capacity of the affected individual to perform his daily activities like bathing, brushing, dressing etc which may have reflected as a change in FIM score. Improvement in bladder sensation and control was also recorded. Few patients changed to self intermittent catheterization from indwelling catheter and condom catheter. 7 patients showed improved healing of pressure sores. Improved ambulation (14.28%), transfers (12.5%) and bed mobility (12.5%) could have accelerated the healing of these pressure sores. This suggests that cell transplantation in combination with rehabilitation may prevent secondary complications of SCI along with improving the quality of life of these patients and making them independent in activities of daily living. These improvements have enabled some patients to acquire vocational training and occupation.

The functional outcome based on age, type of injury, cause of trauma, chronicity and rehabilitation was also analyzed in detail. All the patients (100%) below the age of 18 years showed improvement in FIM score. Whereas 41% and 42% patients in the group of 18-35 years and more than 35 years respectively showed improvement. Younger patients respond better to cell transplantation as compared to adults as they have faster rate of recovery [27], which could be due to more availability and potency of stem cells and greater neuroplasticity. Improvement was observed in FIM irrespective of cause of injury. Based on the chronicity of injury, more number of patients in 1-3 years group showed functional improvement. This may suggest that early intervention is beneficial since increase in chronicity may lead to scar formation that makes repair difficult. 55.55% of the 18 patients who did not undergo rehabilitation showed improvement. And

6.84% of the 38 patients who had undergone rehabilitation before the intervention, also showed increase in FIM score. This indicates

that along with rehabilitation cell transplantation also played an important role in functional outcome.

On comparing the results of the current study on cervical SCI patients with our previously published data on thoracolumbar SCI [28], we found that the effect of cell transplantation was better in the thoracolumbar SCI group. Hence, the neurological and functional outcome also depends on the level of injury along with other factors of SCI. But nevertheless, cell transplantation definitely improves the quality of life of the patients with injury at the cervical level.

The study design was non-randomized, uncontrolled and open labeled, which was one of the limitations. Though there is a lack of control group, the patients may serve as their own control due to chronic nature of SCI (mean duration of injury was 5 years 4 months) and thus presumed to have reached a plateau stage. A multicenter, randomized controlled trial needs to be conducted to appropriately study the efficacy of cell transplantation. Also, there were no markers used to track the migration and fate of the injected cells. The improvements among all the patients may vary due to varied compliance of every patient to rehabilitation.

Based on our results, we conclude that autologous BMMNCs in combination with rehabilitation promote functional recovery in chronic cervical SCI patients. It has a potential to enhance the functional independence in daily activities and thereby improve the quality of life of these patients. However, large multicenter, controlled studies are required to ascertain the efficacy of cell transplantation in chronic cervical SCI. Various other cell types, routes of cell transplantation, window period of administration and adequate number of doses need to be determined to achieve maximum benefits.

References

1. Kraus KH (1996) The pathophysiology of spinal cord injury and its clinical implications. *Semin Vet Med Surg (Small Anim)* 11: 201-207.
2. Deumens R, Koopmans GC, Honig WM, Maquet V, Jérôme R, et al. (2006) Chronically injured corticospinal axons do not cross large spinal lesion gaps after a multifactorial transplantation strategy using olfactory ensheathing cell/olfactory nerve fibroblast-biomatrix bridges. *J Neurosci Res* 83: 811-820.
3. Horner PJ, Gage FH (2000) Regenerating the damaged central nervous system. *Nature* 407: 963-970.
4. Wanner IB, Deik A, Torres M, Rosendahl A, Neary JT, et al. (2008) A new in vitro model of the glial scar inhibits axon growth. *Glia* 56: 1691-1709.
5. Guo X, Bu X, Li Z, Yan Z, Jiang J, et al. (2012) Comparison of autologous bone marrow mononuclear cells transplantation and mobilization by granulocyte colony-stimulating factor in experimental spinal injury. *Int J Neurosci* 122: 723-733.
6. Tharion G, Indirani K, Durai M, Meenakshi M, Devasahayam SR, et al. (2011) Motor recovery following olfactory ensheathing cell transplantation in rats with spinal cord injury. *Neurol India* 59: 566-572.
7. Deng LX, Deng P, Ruan Y, Xu ZC, Liu NK, et al. (2013) A novel growth-promoting pathway formed by GDNF-overexpressing Schwann cells promotes propriospinal axonal regeneration, synapse formation, and partial recovery of function after spinal cord injury. *J Neurosci* 33: 5655-5667.
8. Franzen R, Schoenen J, Leprince P, Joosten E, Moonen G, et al. (1998) Effects of macrophage transplantation in the injured adult rat spinal cord: a combined immunocytochemical and biochemical study. *J Neurosci Res* 51: 316-327.
9. Cheng I, Mayle RE, Cox CA, Park DY, Smith RL, et al. (2012) Functional assessment of the acute local and distal transplantation of human neural stem cells after spinal cord injury. *Spine J* 12: 1040-1044.
10. Koshizuka S, Okada S, Okawa A, Koda M, Murasawa M, et al. (2004) Transplanted hematopoietic stem cells from bone marrow differentiate into neural lineage cells and promote functional recovery after spinal cord injury in mice. *J Neuropathol Exp Neurol* 63: 64-72.
11. Garbossa D, Boido M, Fontanella M, Fronda C, Ducati A, et al. (2012) Recent therapeutic strategies for spinal cord injury treatment: possible role of stem cells. *Neurosurg Rev* 35: 293-311.
12. Carlson RV, Boyd KM, Webb DJ (2004) The revision of the Declaration of Helsinki: past, present and future. *Br J Clin Pharmacol* 57: 695-713.
13. Urdzíkóvá L, Jendelová P, Glogarová K, Burian M, Hájek M, et al. (2006) Transplantation of bone marrow stem cells as well as mobilization by granulocyte-colony stimulating factor promotes recovery after spinal cord injury in rats. *J Neurotrauma* 23: 1379-1391.
14. Liu XZ, Xu XM, Hu R, Du C, Zhang SX, et al. (1997) Neuronal and glial apoptosis after traumatic spinal cord injury. *J Neurosci* 17: 5395-5406.
15. Alexeeva N, Broton JG, Suys S, Calancie B (1997) Central cord syndrome of cervical spinal cord injury: widespread changes in muscle recruitment studied by voluntary contractions and transcranial magnetic stimulation. *Exp Neurol* 148: 399-406.
16. Okano H (2003) Making and repairing the mammalian brain: Introduction. *Semin Cell Dev Biol* 14: 159.
17. Hofstetter CP, Schwarz EJ, Hess D, Widenfalk J, El Manira A, et al. (2002) Marrow stromal cells form guiding strands in the injured spinal cord and promote recovery. *Proc Natl Acad Sci U S A* 99: 2199-2204.
18. Wu S, Suzuki Y, Ejiri Y, Noda T, Bai H, et al. (2003) Bone marrow stromal cells enhance differentiation of cocultured neurosphere cells and promote regeneration of injured spinal cord. *J Neurosci Res* 72: 343-351.
19. Chen Q, Long Y, Yuan X, Zou L, Sun J, et al. (2005) Protective effects of bone marrow stromal cell transplantation in injured rodent brain: synthesis of neurotrophic factors. *J Neurosci Res* 80: 611-619.
20. Mehler MF, Rozental R, Dougherty M, Spray DC, Kessler JA (1993) Cytokine regulation of neuronal differentiation of hippocampal progenitor cells. *Nature* 362: 62-65.
21. Bomstein Y, Marder JB, Vitner K, Smirnov I, Lisaey G, et al. (2003) Features of skin-coincubated macrophages that promote recovery from spinal cord injury. *J Neuroimmunol* 142: 10-16.
22. Lawall H, Bramlage P, Amann B (2010) Stem cell and progenitor cell therapy in peripheral artery disease. A critical appraisal. *Thromb Haemost* 103: 696-709.
23. Paul C, Samdani AF, Betz RR, Fischer I, Neuhuber B (2009) Grafting of human bone marrow stromal cells into spinal cord injury: a comparison of delivery methods. *Spine (Phila Pa 1976)* 34: 328-334.
24. Barbash IM, Chouraqui P, Baron J, Feinberg MS, Etzion S, et al. (2003) Systemic delivery of bone marrow-derived mesenchymal stem cells to the infarcted myocardium: feasibility, cell migration, and body distribution. *Circulation* 108: 863-868.
25. Callera F, de Melo CM (2007) Magnetic resonance tracking of magnetically labeled autologous bone marrow CD34⁺ cells transplanted into the spinal cord via lumbar puncture technique in patients with chronic spinal cord injury: CD34⁺ cells' migration into the injured site. *Stem Cells Dev* 16: 461-466.
26. Carvalho KA, Cunha RC, Vialle EN, Osiecki R, Moreira GH, et al. (2008) Functional outcome of bone marrow stem cells (CD45(+)/CD34(-)) after cell therapy in acute spinal cord injury: in exercise training and in sedentary rats. *Transplant Proc* 40: 847-849.
27. Brown KM, Wolfe BB, Wrathall JR (2005) Rapid functional recovery after spinal cord injury in young rats. *J Neurotrauma* 22: 559-574.
28. Sharma A, Gokulchandran N, Sane H, Badhe P, Kulkarni P, et al. (2013) Detailed analysis of the clinical effects of cell therapy for thoracolumbar spinal cord injury: an original study. *Journal of Neurorestoratology* 1: 13-22.

This article was originally published in a special issue, **Frontiers in Stem cells for Neurological Disorders** handled by Editor. Dr. Kuldip Sidhu, University of New South Wales, Australia

Citation: Sharma A, Sane H, Gokulchandran N, Kulkarni P, Thomas N, et al. (2013) Role of Autologous Bone Marrow Mononuclear Cells in Chronic Cervical Spinal Cord Injury-A Longterm Follow Up Study. *J Neurol Disord* 1: 138. doi:[10.4172/2329-6895.1000138](https://doi.org/10.4172/2329-6895.1000138)